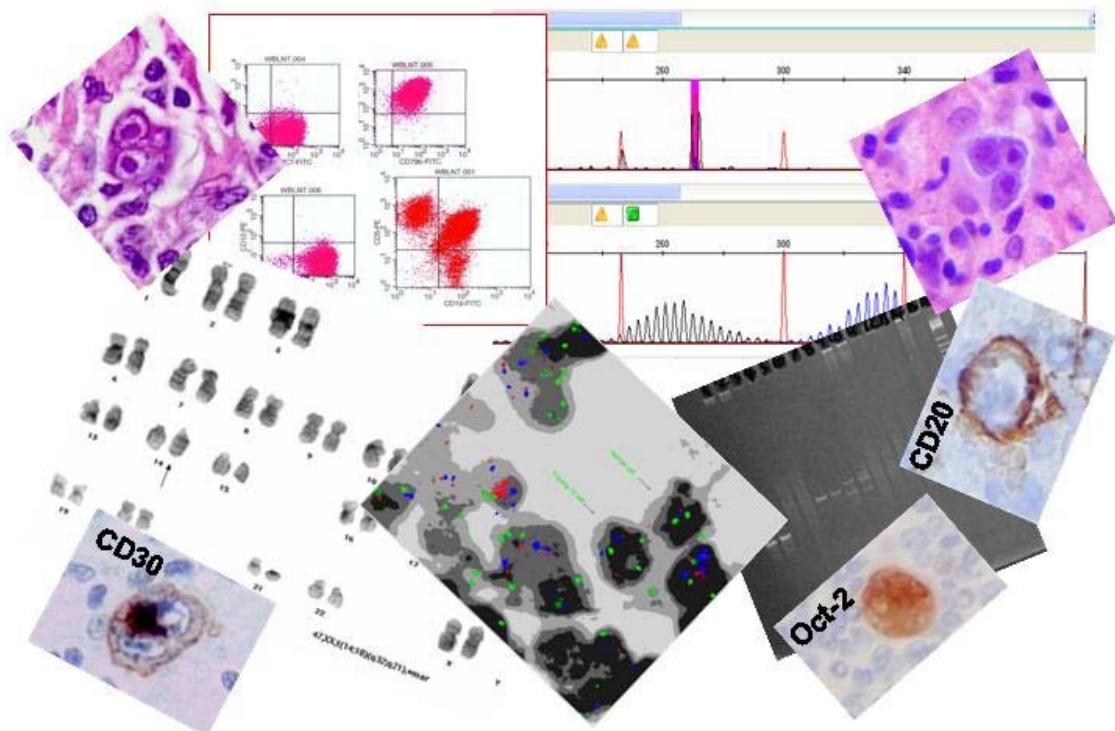


PathSoc 2009, Cardiff

MEET THE EXPERT – LYMPHOMA PATHOLOGY

Dr Stefan Dojcinov, MD FRCPath
Consultant Pathologist
All Wales Lymphoma Panel
Department of Pathology
University Hospital of Wales
Cardiff, UK



SELECTED CASES

Three cases are selected to highlight the general approach and different steps in lymphoma diagnosis.

ONLINE ACCESS TO VIRTUAL SLIDES

The link to the virtual slides set is: <http://dental.uwcm.ac.uk:82/>. This could also be accessed through the AWLP website (<http://www.AWLP.org.uk>). Click the directory "PathSoc 2009 Meet the Expert". Each case is placed in a separate folder containing multiple scans. By clicking a thumbnail the case could be viewed through the internet browser. Image refresh rate and handling speed is improved if the cases are viewed using the ImageScope software. This could be downloaded from: <http://www.aperio.com/download.asp> Click the link ("please click here") at the top of the page and you would be prompted to save the installation file. It is a self installation programme. Once you have installed and started the software, within the thumbnail frame click the link "view: ImageScope". Follow the instruction and the file will open within ImageScope. This file with the Slide Seminar highlight images is also available from the AWLP website.

CASE DETAILS

- Case 1:** Female, 55. Slowly developing axillary lymphadenopathy. Found to have retroperitoneal lymphadenopathy and splenomegaly. Lymph node excision.
- Case 2:** Female, 19. Two month history of lump in left neck with associated sore throat, lethargy and night sweats. Cervical lymph node excised.
- Case 3:** Male, 76. Low grade fever for several months. Skin itching, generally unwell. Enlarged neck, axillary and inguinal lymph nodes. Neck node excised.